



REVIEW ARTICLE

Age-related macular degeneration: Epidemiology, genetics, pathophysiology, diagnosis, and targeted therapy

Yanhui Deng ^{a,b}, Lifeng Qiao ^c, Mingyan Du ^{a,b}, Chao Qu ^c,
Ling Wan ^c, Jie Li ^c, Lulin Huang ^{a,d,*}

^a The Key Laboratory for Human Disease Gene Study of Sichuan Province, Department of Clinical Laboratory, Sichuan Provincial People's Hospital, School of Medicine, University of Electronic Science and Technology of China, Chengdu, Sichuan 610072, PR China

^b Research Unit for Blindness Prevention of Chinese Academy of Medical Sciences, Sichuan Academy of Medical Sciences, Chengdu, Sichuan 610072, PR China

^c Department of Ophthalmology, Sichuan Provincial People's Hospital, School of Medicine, University of Electronic Science and Technology of China, Chengdu, Sichuan 610072, PR China

^d Institute of Chengdu Biology, Sichuan Translational Medicine Hospital, Chinese Academy of Sciences, Chengdu, Sichuan 610041, PR China

Received 1 November 2020; received in revised form 17 January 2021; accepted 21 February 2021
Available online 27 February 2021

KEYWORDS

Age-related macular degeneration;
Diagnosis;
Genetics;
Mechanism;
Target treatment

Abstract Age-related macular degeneration (AMD) is a complex eye disorder and is the leading cause of incurable blindness worldwide in the elderly. Clinically, AMD initially affects the central area of retina known as the macula and it is classified as early stage to late stage (advanced AMD). The advanced AMD is classified into the nonexudative or atrophic form (dry AMD) and the exudative or neovascular form (wet AMD). More severe vision loss is typically associated with the wet form. Multiple genetic factors, lipid metabolism, oxidative stress and aging, play a role in the etiology of AMD. Dysregulation in genetic to AMD is established to 46%–71% of disease contribution, with *CFH* and *ARMS2/HTRA1* to be the two most notable risk loci among the 103 identified AMD associated loci so far. Chronic cigarette smoking is the most proven consistently risk living habits for AMD. Deep learning algorithm has been developed based on image recognition to distinguish wet AMD and normal macula with high accuracy. Currently, anti-vascular endothelial growth factor (VEGF) therapy is highly effective at treating wet AMD. Several new generation AMD drugs and iPSC-derived RPE cell therapy are in the clinical trial stage and are promising to improve AMD treatment in the near future.

* Corresponding author. 32 The First Ring Road West 2, Chengdu, Sichuan 610072, PR China. Fax: +86 28 87393596.
E-mail address: huangluling@yeah.net (L. Huang).
Peer review under responsibility of Chongqing Medical University.

Introduction

The macula is a circular area of diameter 5.5 mm with a center located 17°, or 4.0–5.0 mm, temporal, and 0.53–0.8 mm inferior to the center of the optic disc. The fovea centralis is a small, central pit composed of closely packed cones in the human eye. The fovea is responsible for sharp central vision. The fovea is surrounded by the parafovea belt and the perifovea outer region (Fig. 1A, B). Macular degeneration is the leading cause of severe, irreversible vision loss in people over age 55. It occurs when the macula deteriorates. Because the disease develops as a person ages, it is often referred to as age-related macular degeneration (AMD).

AMD can be classified into four stages.^{1–3} The first stage is normal ageing changes with only small - drusen and no pigment abnormalities. At this stage, the diameter of the drusen is < 63 μm. In the second stage (early AMD), there are some intermediate drusen whose diameter is ≥ 63 μm and ≤ 124 μm but with no retinal pigment epithelium (RPE) cell abnormalities. Stage 3rd is extensive, moderate, at least one large drusen (diameter ≥ 125 μm; intermediate AMD) and RPE abnormalities. Stage 4th, also known as advanced AMD, is concerned with the geographic atrophy (GA) of the fovea or any age-related characteristics of neovascular macular degeneration, as well as resulting in visual loss. Liew confirmed the robustness of the age-related eye disease study (AREDS) simplified severity scale.⁴ Early AMD has the smallest visual impairment, usually accompanied by decreased reading ability, visual distortion, and a black or gray spot in the central vision. Mid-term AMD is characterized by large or moderate vitreous wart membranes or imperfect pigmentation. The central vision of patients with advanced AMD is significantly affected.

Clinically, besides disciform scar which is at the end stage of advanced AMD, advanced AMD is also divided into two categories: dry AMD (Fig. 1C) and wet AMD. Dry AMD is also known as GA, which does not involve blood or serum leakage.⁵ It is characterized by symmetrical eyes, distorted vision, disordered macular pigmentation in both eyes, the disappearance of foveal reflex, varying posterior poles with yellowish-white drusen between Bruch's membrane (BrM) and RPE. In some advanced patients, map-like atrophy of the posterior retina can be observed. Wet AMD can be divided into choroidal neovascularization (CNV, Fig. 1D) and polypoidal choroidal vasculopathy (PCV, Fig. 1E), which involve blood or serum leakage. (At present, it is still controversial whether PCV belongs to wet AMD. On the one hand, PCV and CNV have different characteristics in clinical characteristics and epidemiology. On the other hand, PCV and CNV have similarities in environmental and genetic risk

factors.⁶ In this review, PCV, and CNV are regarded as subtypes of wet AMD). Compared with dry AMD, the visual acuity of patients with wet AMD decreased more rapidly. Most patients with wet AMD suffer from one eye first, and the other eye may not develop for a long time. In CNV, choroidal capillaries grow to the RPE and BrM lesions, resulting in choroidal neovascularization. Because the structure of neovascularization is not perfect, it will lead to a series of pathological changes such as exudation, bleeding and scar, which will further lead to the loss of central vision. PCV is more prevalent in Asians.⁷ The clinical course of PCV is more stable and visual outcomes are more favorable from those of CNV and therefore been described as a separate clinical entity differing from CNV.⁶ In PCV condition, the polypoid neovascularization from the choroid layer can pass through the BrM but would not penetrate the RPE layer. PCV can be divided into type I and type II according to the morphology of the lesions. Type I had abnormal branching vascular network (BVN) and polypoid lesions at the end of the vascular network. Type II had isolated or clustered polypoid lesions, but no obvious branching vascular network or fine reticular vessels.⁸ In this condition, secondary subretinal hemorrhage or submacular hemorrhage may occur.

Epidemiology

Prevalence

The population of AMD is increasing with ethnic and regional differences. From 1990 to 2010, the incidence of blindness and visual impairment caused by AMD was increased.⁹ With population aging worldwide, it is estimated that the number of AMD patients will be increased to 196 million in 2020, 288 million in 2040.¹⁰ Since Asia accounts for more than half of the world's population, the number of cases is expected to reach 113 million by 2040.¹⁰ Because of the highest prevalence of AMD in Europe, the number of future cases in this region is predicted to be second after Asia (Fig. 2).^{10,11} AMD is more common in whites than in blacks.^{12–14} The prevalence rate of AMD in European was 12.33%, Asian was 7.38%, and African was 7.53%.¹⁰ Michele Reibaldi reported that latitude or longitude was negatively correlated with the original or age-standardized prevalence of AMD in the early and late stages ($P < 0.001$).¹⁵ Chinese population accounts for about one-fifth of the world's population. Song Peige reported that the prevalence of AMD varies in different geographical backgrounds in China¹⁶; the prevalence of AMD is concentrated in the most populous areas of south-central China, at 6.64% (95% CI = 5.12–8.52) and 6.74% (95%

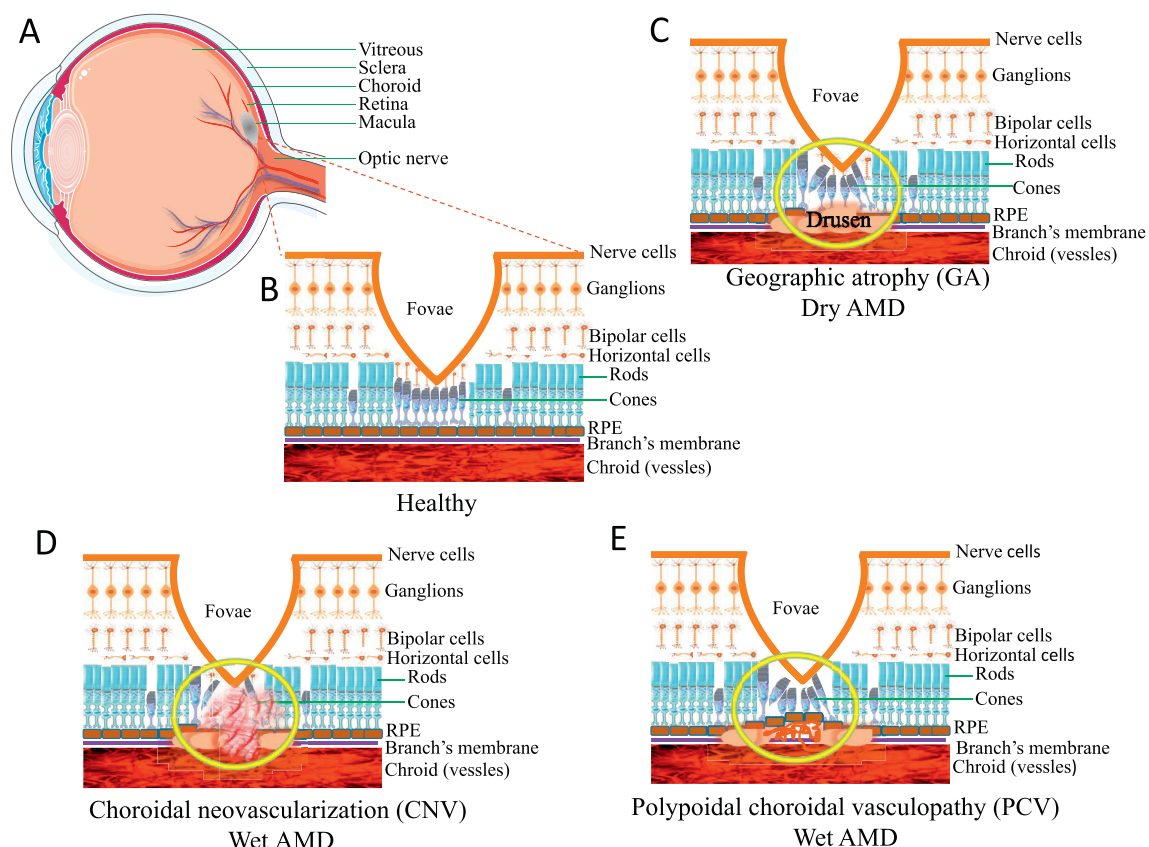


Figure 1 Neovascularization and drusen formation. **(A)** A cross section of a normal human eye showing the location of the macula. An oval area with a diameter of 1.5 mm near the fovea is known as the macula. **(B)** It shows the important structure of the retina in the macular area. RPE cells have the function of removing metabolites produced by photoreceptors. The blood vessels in the choroid can transport nutrients and nourish the outer retina. **(C)** The formation and location of drusen is shown. Drusen formation will lead to retinal tissue atrophy and Bruch membrane calcification rupture, further leading to AMD. **(D)** This picture describes a choroid polypoid lesion. **(E)** This picture shows the proliferation of new blood vessels.

CI = 5.20–8.65) in 2000 and 2010, respectively, and increases with the decrease of latitude.

General risk factors

There are several risk factors for AMD, such as ageing, race, blood pressure, and lifestyle. Ageing is a strong risk factor for the development of AMD. Blue iris is more likely to develop AMD than the brown iris.¹⁷ Systemic factors such as cardiovascular disease are also risk factors for AMD¹⁸; elevated blood pressure^{17,19} and atherosclerosis²⁰ can increase the risk of AMD. The presence of diabetic retinopathy (DR), high-density lipoprotein (HDL),²¹ obesity and high systolic blood pressure increase the risk of AMD in diabetic patients.²² Also, Ronald et al reported that the baseline level of serum cystatin C was associated with the incidence of early AMD and wet AMD.²³ Studies show that smoking and heavy drinking increase the risk of AMD.^{24–26} Lutein and zeaxanthin can reduce the risk of AMD, vitamin C, vitamin E, vitamin D, zinc oxide can prevent the occurrence of AMD.^{27,28} Increase fish intake can reduce the risk of AMD,^{29–31} DHA and EPA may slow the occurrence of AMD.^{32,33} In addition, lunch break is associated with a lower incidence of advanced AMD.³⁴ People who divorced or

separated were three times more likely to have advanced AMD than married people.³⁴

Genetics

Associated loci

Genetic factors had a strong impact on the pathogenesis of AMD,³⁵ totally 103 AMD-related genes or loci have been reported. *CFH* and *HTRA1* loci are the two major associated loci for AMD. In 2005, researchers first linked the 402H allele of *CFH* to an increased risk of AMD.^{36–38} *CFH* is a key regulator of the complement pathway, located in chromosome 1q32. *CFH* 402H disable to transport oxidative lipids out of the RPE layer, destroys the regulatory function of *CFH* in inhibiting the activation of *C3* to *C3b* and degrading *C3b*, leading to the over-activation of complement, thus increasing the risk of AMD.^{35–40} *CFB* and *C2* are activators of alternative and classical pathways, respectively. *CFB* R32Q and R32Q/IVS10 haplotype has a protective effect for AMD.⁴¹ The mutation R102G (rs2230199) of *C3* is involved in the process of AMD from early to late. Lysate *C3a* of *C3* exists in the vitreous verruca membrane.⁴² *C3a* can induce the expression of *VEGF* and promote the formation of CNV.⁴³ *CFI*

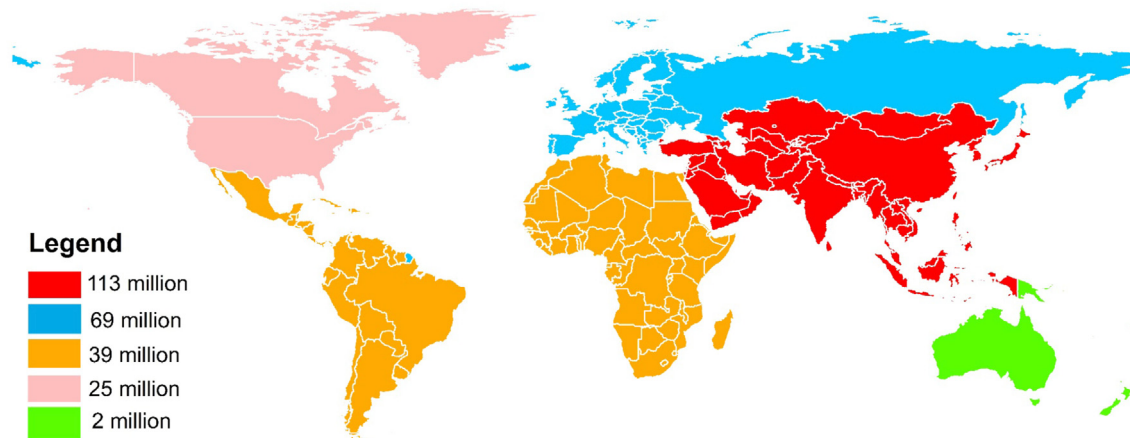


Figure 2 The predicted global prevalence of AMD in 2040. This figure shows the estimated number of people worldwide with AMD in 2040. Data from REF.10.

is regulated by *CFH* and is a cofactor of inactivation of *C3b*. Study showed that rs10033900, rs11728699, rs6854876, rs7439493 and rs13117504 had protective effects,⁴⁴ while rs2285714 was associated with increased risk for AMD. *HTRA1* is another major effect locus for AMD.^{45–54} Rs10490924 in *HTRA1* promoter region can increase the risk of AMD 15 times.^{49,50,52} *HTRA1* transgenic mice showed BrM and choroid damage, with some pathological features of CNV and PCV.

Some AMD genes related to lipid metabolism. *APOE* is a key regulator of lipid and cholesterol transport in the central nervous system. Allele haplotypes of *APOE* were $\epsilon 2$, $\epsilon 3$ and $\epsilon 4$. The risk of AMD in carriers of $\epsilon 4$ is lower than that in people with $\epsilon 3$ genotype. The good mobility of $\epsilon 4$ enables lipid, cholesterol and RPE degradation products to better cross BrM from RPE, otherwise, these substances accumulate in BrM to cause drusen and AMD.^{55–57} *APOE* $\epsilon 2$ seems to enhance the expression of vascular growth factor and fibroblast growth factor RPE cells.⁵⁸ Therefore, *APOE* $\epsilon 4$ can reduce the incidence and progression of AMD compared with *APOE* $\epsilon 2$. In addition, *TIMP3* is involved in RPE aging and sorbite dystrophy.^{59,60} The rs9621532 allele and nearby *TIMP3* variants were associated with increased AMD risk. *LIPC* is also associated with AMD, among which rs10468017 is most related.⁶¹ *CETP*, *LPL*, and *ABA1* have been demonstrated to express in the retina,^{61,62} which is associated with AMD may through affecting the formation of drusen. Rs2511989 encodes *C1INH* in *SEPRING1* gene. *C1INH* is a suppressor of complement classic and lectin pathway activation. It is highly genotypically related to AMD.⁶³

So far, at least 103 AMD associated loci have been identified according to GWAS Catalog (<https://www.ebi.ac.uk/gwas/>) and other publications (Table 1). They are involved in complement factors, lipid metabolism, angiogenesis, immune, cell motion, cytoskeleton, apoptosis and proliferation, cell junction, collagen and etc. Most of the reported genes are associated with all types of AMD and involved in multiple functions (Fig. 3 and Supplementary materials 1). *TLR3* is only associated with dry AMD, which can participate in innate immunity and plays a role as

pathogen recognition receptors in RPE, leading to apoptosis when induced by cytokines. A rare SNP rs77466370 in *FGD6* is only associated with PCV.⁶⁴

Interaction between genes and environmental factors

Some AMD-related genes and environmental factors (such as smoking and so on) interact together to influence the occurrence and development of AMD. Smoking changed the binding of *CFH* to *C3*, lowered the level of *CFH* in plasma,^{65,66} and the rs1061170 variant changed the binding ability of *CFH* to *C3b*. Therefore, rs1061170 carriers have a stronger impact on AMD risk among smokers.^{39,50,67–70} Smoking also increases the risk of all people with the *HTRA1* genotype.⁷¹ AREDS reported a significant interaction between *CFH* 402H and BMI.⁷⁰ Blue Mountains Eye Study (BMES) found that increasing fish intake in *CFH* 402Y carriers had a stronger protective effect on late AMD.⁷² Intake of antioxidant nutrients also reduced the risk of early AMD in people with high genetic risk of *CFH* and *HTRA1* loci.^{73,74} Similar to *CFH* variants, when both *HTRA1* variants and higher C-reactive protein (CRP) levels are present, the risk of AMD increases.⁷⁵ In addition, the potential interaction between chromosome 6q16.2 and 18q22.1 and smoking significantly increased the risk of AMD in long-term smokers.⁷⁶ Schmidt et al found that *APOE* genotype had an impact on the smoking-related risk of AMD, and had a greater impact on CNV, and smoking was the most harmful to carriers of apolipoprotein $\epsilon 2$.^{77,78}

Mechanism/pathophysiology

RPE cell senescence

A series of changes caused by aging of RPE cells can lead to AMD. The ageing RPE cells break the balance of enzymes in the extracellular matrix in the macular area gathers on the

Table 1 Classification of AMD related genes.

Type	Genes (region, SNP)
Complement factors	<i>C9</i> (5p13.1, rs62358361), <i>C3</i> (19p13.3, rs2230199), <i>C2</i> (6p21.33, rs116503776), <i>CFHR4</i> (1q31.3, rs2171106), <i>CFH</i> (1q31.3, rs10922109), <i>MBL2</i> (10q21.1, rs6480975), <i>CFI</i> (4q25, rs10033900), <i>CFB</i> (6p21.33, rs116503776), <i>CFHR2</i> (1q31.3, rs2171106)
Lipid metabolism	<i>CETP</i> (16q13, rs5817082), <i>APOE</i> (19q13.32, rs429358), <i>LIPC</i> (15q21.3, rs2043085), <i>ABCA1</i> (9q31.1, rs2740488), <i>LHFP</i> (13q14.11, rs8002574), <i>ABHD2</i> (15q26.1, rs4932480), <i>TIMP3</i> (22q12.3, rs9621532)
Angiogenesis	<i>FILIP1L</i> (3q12.1, rs13081855), <i>VEGFA</i> (6p21.1, rs943080)
Immune	<i>PVRL2</i> (19q13.32, rs6857), <i>CD34</i> (1q32.2, rs1967689), <i>PILRB</i> (7q22.1, rs7803454), <i>SDK1</i> (7p22.2, rs55869773), <i>ACKR3</i> (2q37.3, rs56072732)
Cell motion	<i>POSTN</i> (13q13.3, rs9646096), <i>TNXB</i> (6p21.32, rs12153855), <i>CNN2</i> (19p13.3, rs67538026)
Cytoskeleton	<i>CCSER2</i> (10q23.1, rs113544501), <i>POC5</i> (5q13.3, rs79069165), <i>HTRA1</i> (10q26.13, rs3750846), <i>ARMS2</i> (10q26.13, rs3750846)
Apoptosis and proliferation	<i>TNFRSF10A</i> (8p21.3, rs13278062), <i>CTRB2</i> (16q23.1, rs72802342), <i>NOTCH4</i> (6p21.32, rs2071277), <i>FRK</i> (6q22.1, rs1999930), <i>PHACTR3</i> (20q13.32, rs843818), <i>PKNOX2</i> (11q24.2, rs1077952), <i>KRAS</i> (12p12.1, rs73296436), <i>IER3</i> (6p21.33, rs3130783), <i>TRIM29</i> (11q23.3, rs61900473), <i>TGFBFR1</i> (9q22.33, rs334353)
Cell junction	<i>GJA1</i> (6q22.31, rs9482193), <i>CDH22</i> (20q13.12, rs6032755)
Mitochondrial	<i>NDUFC2</i> (11q14.1, rs113553030), <i>XRCC6BP1</i> (12q14.1, rs12368533), <i>UQCRRF51</i> (19q12, rs741449), <i>TOMM40</i> (19q13.32, rs6857), <i>SOD2</i> (6q25.3, rs2842992), <i>ACAD10</i> (12q24.12, rs61941274), <i>MT-ND5 x ABHD2</i> (15q26.1, rs267606894 x rs4932480)
Ionic channel	<i>KCNMA1</i> (10q22.3, rs76150532), <i>KCNJ3</i> (2q24.1, rs1445653), <i>TRPM1</i> (15q13.3, rs7182946), <i>EFCAB14</i> (1p33, rs59182762), <i>KCTD15</i> (19q13.11, rs10404384), <i>TRPM3</i> (9q21.12, rs71507014)
Ubiquitination	<i>NPLOC4</i> (17q25.3, rs6565597)
Transcription	<i>PCF11</i> (11q14.1, rs4293143), <i>TRIM24</i> (chr7:138166004, hg19), <i>NELFE</i> (6p21.33, rs116503776), <i>RREB1</i> (6p24.3, rs11755724), <i>GLI3</i> (7p14.1, rs2049622), <i>KLF6</i> (10p15.1, rs12411753), <i>ATF7IP2</i> (16p13.13, rs28368872), <i>BAZ1A</i> (14q13.2, rs6571690), <i>EFCAB14</i> (1p33, rs59182762), <i>KHDRBS3</i> (8q24.23, rs200534628), <i>LYAR</i> (4p16.3, rs150938341), <i>NUPR1L</i> (7p11.2, rs148800247), <i>TLE4</i> (9q21.31, rs11545434)
Transport	<i>SLC16A8</i> (22q13.1, rs8135665), <i>SLC29A3</i> (10q22.1, rs7091537), <i>SLC44A4</i> (6p21.33, rs12661281), <i>TRAPPC9</i> (8q24.3, rs117659209), <i>ADAMTS9</i> (3p14.1, rs6795735)
Nerve	<i>SYN3</i> (22q12.3, rs5754227), <i>CELSR1</i> (22q13.31, rs2337055), <i>CNTN6</i> (3p26.3, rs77360121), <i>DPF3</i> (14q24.2, rs12887388), <i>MBP</i> (18q23, rs1789110), <i>TNR</i> (1q25.1, rs58978565), <i>HERC1</i> (15q22.31, rs15q22.31)
Cluster protein family	<i>PLXNC1</i> (12q22, rs17296444)
Helicases	<i>SKIV2L</i> (6p21.33, rs406936)
Adenylate cyclase	<i>ADCY5</i> (3q21.1, rs6762009)
GTPase or ATPase	<i>ARHGAP21</i> (10p12.1, rs12357257), <i>ATP6V0D1</i> (16q22.1, rs1471142), <i>FGD</i> (12q22, rs10507047)
Tyrosinase	<i>TYR</i> (11q14.3, rs621313)
BBSome	<i>BBS9</i> (7p14.3, rs202162020)
Transmembrane protein	<i>TMEM97</i> (17q11.2, rs11080055), <i>TSPAN11</i> (12p11.21, rs55916253)
DNA binding protein	<i>RAD51B</i> (14q24.1, rs61985136), <i>TSN</i> (2q14.3, rs72837798)
Transferase	<i>KMT2E</i> (7q22.3, rs1142), <i>B3GALTL</i> (13q12.3, rs9564692), <i>UGT2B7</i> (4q13.2, rs112243525), <i>HS3ST4</i> (16p12.1, rs79590629)
Collagen	<i>COL8A1</i> (3q12.1, rs140647181), <i>COL10A1</i> (6q22.1, rs1999930), <i>COL4A3</i> (2q36.3, rs11884770)
Noncoding RNA	<i>ADAMTS9-AS2</i> (3p14.1, rs62247658), <i>LINC00470</i> (18p11.32, rs2186849), <i>LINC00588</i> (8q12.1, rs72657107), <i>LINC00900</i> (11q23.3, rs431911), <i>PCDH9-AS3</i> (13q21.32, rs1359191), <i>LOC101060498</i> (4p14, rs12498917), <i>LOC101927280</i> (5q23.1, rs61287758), <i>LOC101927797</i> (21q21.1, rs2205502), <i>LOC101929681</i> (5p13.3, rs139161960), <i>LOC153910</i> (6q24.2, rs63337561), <i>LOC729987</i> (1p21.3, rs12727789)
Others	<i>INHBB</i> (2q14.2, rs6721654), <i>ZPLD1</i> (3q12.3, rs17822656), <i>HORMAD2</i> (22q12.2, rs713875), <i>CST5</i> (20p11.21, rs4815244), <i>CTRB2</i> (16q23.1, rs72802342), <i>EXOC5</i> (14q22.3, rs75165563), <i>IGFBP6</i> (12q13.13, rs11170417), <i>PDHA2</i> (4q22.3, rs62315917), <i>PRLR</i> (5p13.2, rs114092250), <i>RDH5</i> (12q13.2, rs3138141), <i>STOX2</i> (4q35.1, rs11132213), <i>TRIB2</i> (2p24.3, rs10191751), <i>C20orf85</i> (20q13.32, rs201459901), <i>C4orf14</i> (4q12, rs1713985), <i>C6orf223</i> (6p21.1, rs2295334), <i>C8orf42</i> (8p23.3, rs722782), <i>C9orf91</i> (9q32, rs41278671)

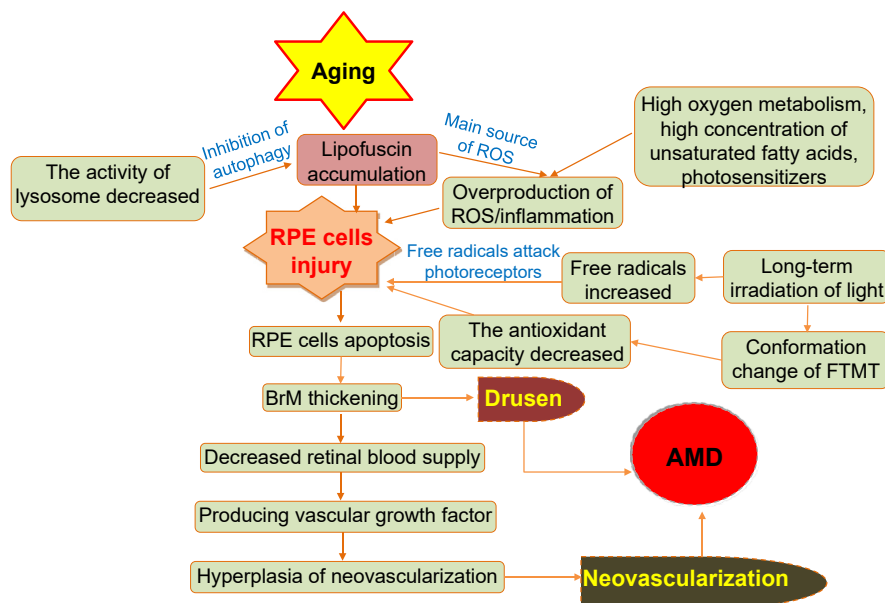


Figure 4 The formation of AMD during aging. This diagram shows the non-genetic mechanisms of AMD induced by RPE cell senescence, oxidative stress, hemodynamics and so on during aging.

to complement activation and inflammation.⁹⁵ Most complement proteins do not diffuse through BrM, but *C5a* released after the activation of complements of AMD pass through BrM, leading to inflammation and angiogenesis.⁹⁶ There is growing evidence that the targeted regulation of complement-specific proteins is expected to become a therapeutic method for AMD. Local inhibition of complement activation is considered a promising treatment for advanced AMD. At present, some studies have found potential complement cascade inhibitors, which may slow down the progress of AMD.⁹⁷ Also, Calippe et al found that the combination of CFH and mononuclear phagocytes (MP) inhibited CD47-mediated MPs clearance, while MPs maintained the steady state of subretinal space.⁹⁸ Therefore, inflammation and immunity are also closely related to the occurrence of AMD.

Neovascularization

VEGF is one of the main risks of wet AMD, which plays an important role in the occurrence of CNV and PCV.^{64,69} Overexpression of vascular-promoting cytokines (such as VEGF, PDGF) and reduction of expression of inhibitory cytokines (ES, TIMP and so on) can lead to excessive proliferation of neovascularization. Studies have shown that the Pulsatile ocular blood flow (POBF) and pulse amplitude (PA) in exudative AMD patients are lower than those in non-exudative AMD patients. The thickening of BrM may lead to increased choroidal vascular resistance, and the decrease of choroidal blood flow may be related to the formation of CNV.^{99–102} In addition, choroidal vitreous warts and abnormal pigmentation also increase the risk of AMD. After one eye progresses to advanced AMD, the five-

year risk of occurrence of AMD of the second eye is estimated to be between 30% and 40%, which is much higher than that in the normal population.¹⁰³

Other mechanisms

In addition to the above factors that are closely related to the occurrence and development of AMD, other factors, such as autophagy, hemodynamics and circadian rhythm, are also believed to be related to AMD. Autophagy is a lysosomal pathway for the degradation of cytoplasmic proteins and damaged organelles. Protein aggregates are transported to lysosomes via autophagy. With the increase of age and RPE cells aging, lysosomal enzyme activity decreased. Autophagy was reduced to remove mitochondria and protein aggregates, outside cells, thus accelerating the accumulation of lipofuscin, further leading to the development of AMD.^{104,105} Golestaneh et al found that the autophagic flux of RPE in AMD patients was lower than that in normal RPE controls.¹⁰⁶

There is a classical theory about the occurrence and development of AMD, namely hemodynamics, which holds that choroidal vascular dysfunction is the basis of AMD. Atherosclerotic changes in the blood supply to the eye are now known as neovascular AMD. The modern hemodynamic theory proposed by Friedman in 1997 that AMD occurs because of the change of choroidal blood flow caused by the increase of choroidal and scleral sclerosis.¹⁰⁷ Blood lipid deposition and atherosclerosis result in thickening of the vascular wall, stenosis of vascular lumen, and decreased compliance of vascular wall, resulting in decreased choroidal blood flow and abnormal choroidal perfusion, resulting in insufficient perfusion of RPE cells or Bruch

membrane injury, which ultimately leads to AMD. The view that choroidal hemodynamics contributes to the progress of AMD has been supported by recent clinical and experimental data.¹⁰⁸

Some studies have found that cyclic genes may play a role in regulating retinal vascularization signals in retinopathy.¹⁰⁹ In proliferative neovascularization, the expression of retinal rhythm genes is destroyed.¹¹⁰ Whether circadian rhythm disorder will affect the occurrence and development of AMD remains to be further studied. In addition, the imbalance of protein homeostasis may be one of the potential mechanisms leading to AMD.

Diagnosis

The diagnostic methods of AMD include fundus imaging, fluorescein angiogenesis (FA), indocyanine green angiography (ICGA), optical coherence tomography (OCT), Optical coherence tomography angiography (OCTA) and artificial intelligence (AI). These techniques play an important role in the diagnosis of AMD and have their unique advantages.

Fundus imaging

Fundus imaging methods include color photography, monochromatic photography, automatic fluorescence imaging, and fundus angiography, which are useful for AMD diagnosis. Microperimetry is a non-invasive visual function test for the analysis of fixation and central visual field defects, especially for AMD. Compared with standard automated perimetry (SAP), microperimetry has the advantages of real-time imaging of fundus and eye tracking.¹¹¹ GA can be observed in the eyes of patients with dry AMD drusen, subretinal hemorrhage and pigment epithelial detachment (PED) are common in the eyes of patients with wet AMD. These phenotypes can be easily observed in fundus imaging.

FA and indocyanine green angiography (ICGA)

Dyes used for fundus angiography include sodium fluorescein and indocyanine green. FA is a useful method for detecting wet AMD. Indocyanine green angiography (ICGA) is the gold standard diagnostic tool for PCV. Both FA and ICGA are safe, but occasionally serious reactions may occur. Therefore, the potential risk factors of patients must be carefully screened and the risk of angiography should be informed. Under FA, compared with CNV, serous PED or atypical serous PED is more common in PCV. Under ICGA, CNV showed a neovascularization network without polypoid structure, while abnormal vessels in PCV were more robust with terminal polypoid or aneurysmal cluster with high fluorescence.

Optical coherence tomography (OCT)

OCT is a non-invasive method that can display anatomical cross-sectional information about retina, RPE, and choroid. In early AMD, abnormalities in drusen and RPE can be observed by OCT, which helps doctors to determine the

annual signs of disease activity and the risk of progression. In advanced AMD, the activity of disease was monitored by qualitative and quantitative analysis of fluid pools, such as intraluminal cystic fluid, subretinal fluid, and PED, by using OCT.¹¹² Spectral OCT (SD-OCT) has the advantage of sampling information of multiple locations in the optical path at the same time, which improves the speed of diagnosis. It can easily detect and measure the changes in the photoreceptor layer (PRL) on verruca vitreosa.¹¹³ Under OCT, the choroid thickness of wet AMD is greater than that of normal human, while that of dry AMD is less than that of normal human.¹¹⁴

Optical coherence tomography angiography (OCTA)

Optical Coherence Tomography Angiography (OCTA) is a new non-invasive imaging technology, which provides non-invasive characterization and quantification of microvascular system under different retinal conditions.¹¹⁵ OCTA can be used to observe chorionic changes in patients with dry AMD, to detect the presence of CNV and PCV. OCTA has a good resolution of CNV structure in patients with wet AMD, and can observe and classify the orientation of CNV from cross-section.^{116,117} Overall sensitivity of active CNV detection by OCTA was 80.7%.¹¹⁸ Compared with FA, OCTA is less occluded by subretinal hemorrhage.^{119,120} For PCV, a combination of structural OCT and OCTA can be used to screen for PCV with 82.6% sensitivity and 100% specificity.¹²¹ Therefore, OCTA can provide clearer vascular details and better detect and quantify CNV lesions in AMD patients. The superficial and deep vascular density of dry AMD patients was significantly lower than that of healthy people. In patients with wet AMD, significant loss of deep choroid vessels and villi muscle was observed. Among them, CNV patients have reduced chorionic capillary perfusion and deeper choroid.¹²²

Artificial intelligence diagnosis technology

With the development of artificial intelligence (AI) technology, AI has great potential in the diagnosis of ophthalmic diseases. Kermany et al have proved that the classification effect of the model based on the neural network resume on AMD and diabetic macular edema is equivalent to that of human experts.¹²³ Similarly, Treder et al used deep learning to train and verify 1112 SD-OCT images of AMD to distinguish exudative macula and normal macula. The classifier model established has achieved good results (the training accuracy and validation accuracy are 100%, the average score of AMD experimental group and control group are more than 0.9).¹²⁴ With the development of network technology and the advent of 5G era, AI technology will be constantly optimized. The advantages of AI technology in assisting ophthalmologists to judge the patient's condition and to assist doctors to formulate the optimal treatment plan will also become increasingly prominent. However, the application of AI depends on database, so the establishment of high-quality database is still a challenge for the application of AI in disease diagnosis.

Table 2 Current therapeutic drugs for wet AMD.

Drug	Attribute	Mechanism of action	Date of approval	Note
Pegaptanib (Macugen)	Anti-VEGF aptamer	Binding to vascular endothelial growth factor 165 prevents its binding to vascular endothelial growth factor receptor	FDA approved it for wAMD treatment in 2004	Visual acuity can not be stabilized well after treatment.
Ranibizumab	Anti-VEGF monoclonal antibody	Binding with VEGF 165, 121 and 110	It was approved by FDA in 2006 for DR and in Europe in 2009 for visual impairment caused by wAMD, RVO, DR and CNV.	Therapeutic effect is better than photodynamic therapy.
Bvacizumab	Humanized anti-VEGF monoclonal antibody	Inhibition of angiogenesis	FDA approved it as a cancer inhibitor in 2004, but it has not yet been approved for ophthalmic treatment	Target molecule and effect are similar to those of ranibizumab
Aflibercept (Eylea)	Humanized anti-VEGF fusion protein	Binding to VEGF-A, VEGF-B and PGF	FDA approval for diabetic macular edema and DR in 2011	It has the same effect as ranibizumab
Conbercept	Anti-VEGF Fusion Protein	Binding to VEGF-A, VEGF-B and PGF	In 2013, it was approved by CFDA for the treatment of wAMD, and was awarded "the most innovative drug with clinical value" in phase III clinic of USA.	Adverse reactions are weak and can be recovered without treatment, which is more economical than ranibizumab
Triamcinolone acetonide	Glucocorticoid	Inhibition of angiogenesis, the specific mechanism of action is not yet clear.	On February 4, 2019, the FDA accept the application for new drug triamcinolone acetonide suspension (xipere)	The effect of single use is not significant.
Brolucizumab (Beovu, RTH258)	anti-VEGF antibody	binds to the VEGF-A subtype	approved in the United States in 2019	After one year of treatment, patients treated with BEOVU showed similar visual improvement as patients treated with aflibercept.
Abicipar pegol	anti-VEGF molecule	Using DARP in technique to mimic antibody, target VEGF	Not yet approved, phase III completed	
Faricimab	Bi-specific antibody	anti-Ang-2 antibody and anti-VEGF-A antibody	Not yet approved, phase III completed	
OPT-302	A fusion protein composed of the 1–3 of VEGFR-3 and Fc	By binding to VEGF-C or VEGF-D, they block their binding to VEGFR-2 or VEGFR-3 on the surface of endothelial cells in blood vessels or lymphatic vessels.	Phase III clinical trials are planned for 2021	The effect of combination with ranibizumab is better than that of using alone
Dorzolamide-timolol	Carbonic anhydrase inhibitor	Acting by decreasing the production of aqueous humour	phase III clinical trials are underway	Combined with anti-VEGF Drugs to reduce retinal effusion
RGX-314	A gene vector containing anti-VEGF gene	Adenovirus AAV8 carries the monoclonal antibody gene of VEGF and is injected under the retina	Phase II clinical trials are underway. Good results have been achieved in phase I/IIa clinical trials.	A gene therapy method

Table 2 (continued)

Drug	Attribute	Mechanism of action	Date of approval	Note
GB-102 (Sunitinib)	multi-target receptor tyrosine kinase inhibitors	VEGF is blocked by inhibiting the VEGF receptor ((VEGFR1, VEGFR2, VEGFR3)	Phase II clinical trials begin in September 2019.	
X-82 (Vorolanib)	VEGFR and PDGFR inhibitors	Antiangiogenesis is achieved by inhibiting VEGFR and PCGFR	Phase I clinical trials were completed in December 2019, phase II clinical trials are underway	
HMR59 (AAVCAGsCD59)	Adenovirus vector containing e soluble protein CD59 (sCD59)	Making the retinal cells continue to produce (sCD59) soluble proteins to block the final step of the complement cascade	phase II clinical trials are plan for 2020	
CM082 tablets	VEGFR/PDGFR dual inhibitors	Antiangiogenesis is achieved by inhibiting VEGFR and PCGFR	Phase II clinical trials began in 2019	Oral drug
RG7716	Bi-specific monoclonal antibody	Binds and inactivates VEGF-A and ang-2	Phase II clinical trials were completed in 2018 and phase III clinical trials are planned	Vitreous injection, it works better in combination with ranibizumab
IBI302	Dual target antibody	Both VEGF and complement are targeted	Phase I clinical trials began in 2019	
ADV-022	A gene vector containing anti-VEGF gene	AAV-anti-VEGF therapy method	Phase I clinical trials. are underway, start to collect participants in the second half of 2020	It's injected into the vitreous instead of under the retina
TAB014	anti-VEGF antibody	Blocking the signal transmission mediated by VEGF can inhibit the growth of new blood vessels	Phase I clinical trials have been completed in January 2020	Registered as a class 1 new drug in China

PDGF: platelet-derived growth factor; PGF: placental growth factor; wAMD: wet age-related macular degeneration; DR: diabetic retinopathy; RVO: retinal vein occlusion; CNV: choroidal neovascularization; Ang-2: angiopoietin-2; DARP: designed ankyrin repeat protein; PDGFR: platelet-derived growth factor receptor, VEGFR: vascular endothelial growth factor receptor.

Treatment

Laser and radiotherapy

In 1999, Reichel et al began to treat CNV by transpupillary thermotherapy (TTT).¹²⁵ Because its therapeutic effect is only to block the existing CNV, it will also produce complications, such as choroidal atrophy. It is easy to recur, so it is seldom used at present. In addition, studies^{126,127} have shown that TTT combined with other angiogenic drugs, such as triamcinolone acetate or ranibizumab, can be used as a therapeutic regimen for wet AMD, but its efficacy needs further evaluation. Besides TTT, laser therapy includes photodynamic therapy (PDT). PDT can be combined with ranibizumab. PDT combined with anti-vascular therapy for PCV is an effective method.¹²⁸ Although laser therapy can inhibit the growth of new blood vessels, it can not ensure that no new blood vessels grow. The laser may also destroy normal tissue around the retina. Therefore, it is necessary

and important to improve the existing treatment methods and develop new treatment methods for AMD.

Anti-VEGF treatment

The key to the treatment of exudative AMD is to inhibit the formation of neovascularization,¹²⁹ and intraocular injection of drugs to inhibit VEGF has become the main treatment for wet AMD.^{130–132} Blindness and the density of choroidal capillaries decreases in patients treated with anti-vascular therapy.^{133,134} The main drugs include pegaptanib, ranibizumab, bevacizumab, aflibercept and conbercept (Table 2). Pegaptanib^{135,136} and ranibizumab are anti-VEGF monoclonal antibody fragment. Aflibercept is a fusion protein of VEGF binding. It is formed by the second binding of human VEGF receptor (VEGFR) –1 to the third binding domain of human VEGF receptor-2 (VEGFR2), and then binding to the Fc region of human immunoglobulin G-1. Aflibercept can bind to all subtypes of VEGFA and VEGFB.

It is a new generation of anti-VEGF after pegaptanib and ranibizumab were approved by the FDA in November 2011. Intravitreal injection of aflibercept two months or monthly after the initial dose of three months was similar safety and tolerance to that of ranibizumab monthly.^{137,138} Conbercept is composed of the binding domain of human VEGFR-1 and VEGFR-2 and the Fc part of human immunoglobulin G-1. It had a strong anti-angiogenesis effect.^{139–141} Intravitreal injection of conbercept was safe and effective and could prevent the growth of lesions and CNV. Brolucizumab is a humanized, single-stranded antibody that targets VEGF and binds to the VEGF-A subtype. It showed good results in phase 3 clinical trials.¹⁴² It was approved by the FDA for the treatment of wet AMD. Faricimab is a bispecific antibody drug that can bind and inactivate angiopoietin-2 (Ang-2) and VEGF-A. The effect of faricimab is similar to that of ranibizumab.¹⁴³ Abicipar pegol is an anti VEGF molecule that uses the designed ankyrin repeat protein (darpin) technology to reduce the level of VEGF. Its half-life in the eye is longer and the effect is more lasting.¹⁴⁴ At least 13 drugs for VEGF related targets are still in developing. Abicipar pegol, Faricimab, TypeOPT-302 and Dorzolamide-timolol are in their phase III clinical trials; RGX-314, GB-102 (Sunitinib), X-82 (Vorolanib), HMR59 (AAVCAGsCD59), CM082 tablets and RG7716 are in their

phase II clinical trials; IBI302, ADVM-022 and TAB014 are in their phase I clinical trials. For dry AMD, there is no effective treatment method currently. However, Heavy dietary intake of specific antioxidants such as carotene, vitamin C, D, E, and zinc may have been shown to slow the progression of a few dry AMD patients.¹⁴⁵

RPE transplantation

Because AMD is mainly related to damage RPE cells which are easy to cultivate and independent of synaptic connections,^{146–148} RPE cells can be transplanted to repair or replace RPE cells in patients. RPE transplantation mainly includes macular translocation, autologous RPE-choroidal transplantation, and RPE cell suspension injection. Macular translocation refers to the displacement of macula on RPE, which can be regarded as functional RPE transplantation. Although it has been proved that the operation can bring long-term visual stability,¹⁴⁹ there will be pigment epithelial cell atrophy under the displaced macula,¹⁵⁰ and it is prone to complications. The advantage of autologous RPE-choroidal transplantation is that the graft can attach to the choroidal vessels in a short time, and the pigment epithelium usually does not grow excessively. Transplantation remains a major challenge for eye

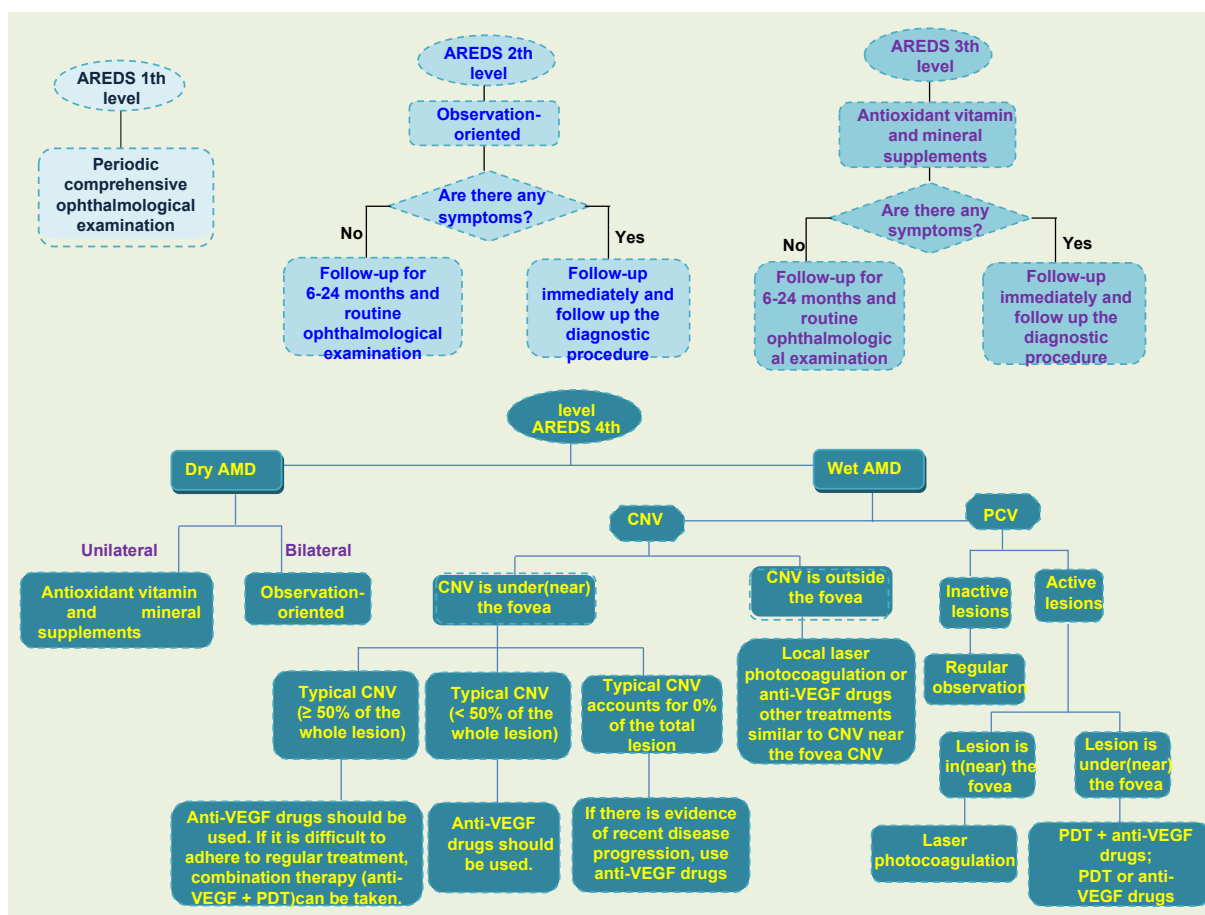


Figure 5 Suggestions on treatment and follow-up of AMD. This is the treatment strategy for AMD. Routine ophthalmic examination and follow-up were the main methods for early and middle stage AMD patients, while appropriate treatment was adopted for advanced AMD patients according to their characteristics.

surgeons. Researchers also tried traditional clamp, aspiration reflux tube into the subretinal space to release implants, micro-thermal gripper using heat-induced graft attachment and peeling, and even using customized devices to deliver implants.^{151,152} RPE cell suspension injection has much fewer complications than macular translocation,¹⁵³ but the transport of cell suspension is still an issue. Researchers have tried to inject cell suspension¹⁵⁴ through scleral choroidal pathway with blunt needle and transport cell suspension^{155,156} through glass cannula. Although RPE cell transplantation is a way for AMD treatment in the clinic, there are still some problems to be solved urgently, such as the transportation of cell suspension and implant delivery, source of cells, the residual RPE removal, the prevention and control of PVR, and the quality of transplanted cells.¹⁵⁷ In addition to RPE transplantation, there are artificial cone transplantation, lower localized macular displacement, 360° macular transposition, and macular transposition combined with 360° retinotomy.^{158–160} Doctors often treat patients differently depending on the severity and type of AMD (Fig. 5).

Stem cell therapy

Stem cell therapy is a new potential therapeutic method for dry AMD treatment. In 2012, researchers first reported the transplantation of human embryonic stem cells (hESC) derived RPE cells into elderly patients with dry AMD.¹⁶¹ They successfully transplanted the cultured hESC-RPE cells into the patients, and no pathological conditions

such as teratoma, abnormal proliferation of hESC-RPE cells were found. Generally speaking, the patients were well tolerated, and the patients' best-corrected visual acuity was also obtained. Researchers designed a biological patch consisting of RPE monolayer derived from hESC.¹⁶² In their clinical trials, the vision of two AMD patients with severe visual impairment was stabilized and improved. Their study demonstrates the feasibility and safety of hESC-RPE patch transplantation as a treatment for dry AMD. One disadvantage of this technique is that local immunosuppression is necessary for hESC-RPE. There is no evidence of adverse proliferation, tumorigenicity or other serious ocular or systemic safety problems associated with transplanted patients. Mandai et al studied the feasibility of transplantation of RPE cells derived from pluripotent stem cells (iPSC) for the treatment of AMD.¹⁶³ iPSC was generated by skin fibroblasts of patients (Fig. 6). The patients' best corrected visual acuity did not improve or deteriorate, but their VFQ-25 score improved.

Gene therapy

Gene therapy is also one of the potential therapies for AMD. Because the eye is a small enclosed microenvironment and has a blood-retinal barrier, it can maintain a high concentration for a long time by injecting a small amount of reagent without being affected by the immune system. Gene therapy achieves the goal of treating diseases by introducing genetic material into patients (Fig. 6). In AMD, AAV2 carriers with VEGF binding proteins are used to inhibit angiogenesis. AAV2-sFLT01 and AAV2-sFLT02 are fused into

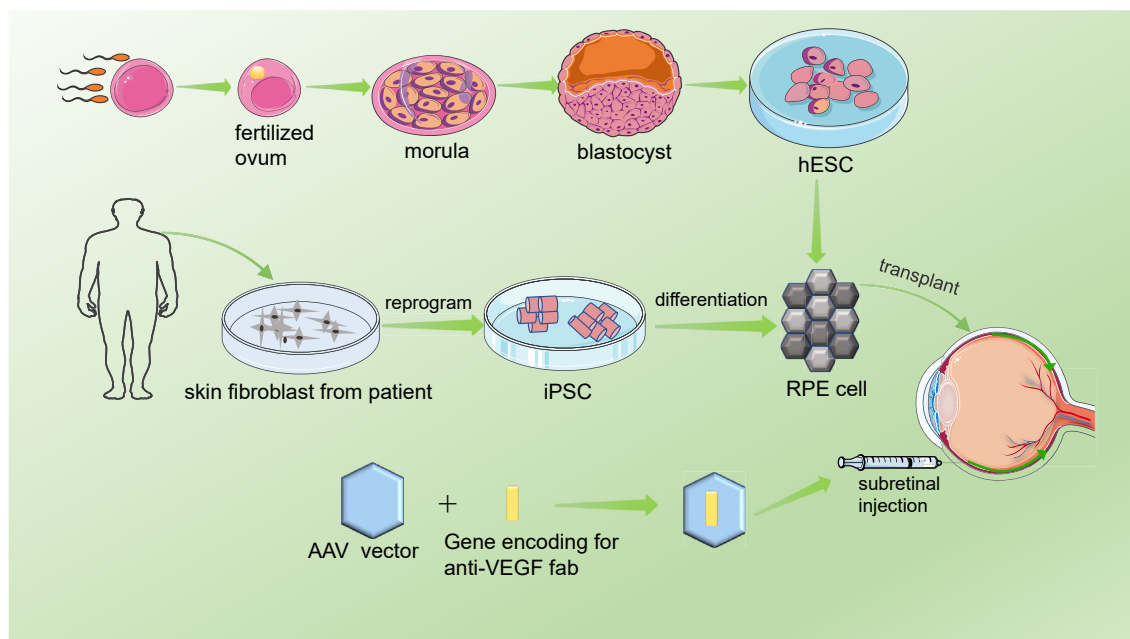


Figure 6 Schematic diagram of cell therapy and gene therapy for AMD. The fertilized ovum was obtained by *in vitro* fertilization, and the fertilized ovum developed into a morula and then a blastocyst. The inner cell population of the blastula was proliferated *in vitro* to obtain embryonic stem cells, which were induced to differentiate into RPE cells and transplanted into the patients' eyes. In addition, skin fibroblasts from the patient were induced to produce pluripotent stem cells, which differentiated into RPE cells and were transplanted into the patients' eyes. Gene therapy is performed mainly by injecting AAV vector carrying vVEGF-binding protein into the subretinal space of patients.

human IgG1 Fc region or its methyl domain and can be used to inhibit CNV.^{164,165} Studies have shown that AAV2 vector-mediated therapy is safe and effective, and can be used as a potential long-term treatment for wet AMD.^{166–170} In addition, viral vectors carrying endostatin and angiostatin also inhibited angiogenesis.^{171–173} Thumann et al successfully transfected PEDF gene using Sleeping Beauty (SB100X) transposon subsystem and microplasmid without antibiotic resistance marker (pFAR4),¹⁷⁴ and isolated iris pigment epithelium (IPE) cells. Li W et al constructed a target inhibitor CR2-sFlt1, which can significantly reduce the expression of VEGF in RPE cells. The CR2 targeting fragment can locate CR2-sflt1 at the site of complement deposition in CNV region. Their research shows that the targeting inhibitor can inhibit CNV with high selectivity.¹⁷⁵ In addition, cytokines are the basis of targeted combination therapy for wet AMD, among which TNF, PDGF or fibroblast growth factor are potential targets for effective combination therapy.¹⁷⁶

Outlook

AMD is a complex disease. There are few effective treatments for dry AMD. Healthy lifestyles, such as proper exercise, maintaining a normal weight, control blood pressure, and cholesterol, are important to reduce the risk of AMD.¹⁷⁷ No smoking, a high level of lutein/zeaxanthin diet such as vitamin C, vitamin E, zinc oxide, lutein/zeaxanthin can reduce the risk of AMD. Also, fish and green vegetables can also reduce the risk of AMD. Treatment strategies for AMD should incorporate a variety of risk factors to avoid and improve drug interventions, and also need to take into account personalized genetic information. The activation of complement components further promotes the development of AMD, so the local inhibition of complement is considered to be a choice for the prevention and treatment of early AMD. Besides, *CFH*, *CFB*, *C2*, *C3* and *CFI* in complement pathway, *HTRA1*, lipids metabolism related genes such as *CETP*, *APOE* etc. are closely related to AMD and are expected to become therapeutic targets besides VEGF pathway. Emerging therapies are likely to open up new avenues for AMD treatment. With the development of technology and research progress, the emergence of new and more effective AMD treatment methods will improve patients' visual acuity,¹⁷⁸ and improve patients' quality of life.

Author contributions

L.H. designed the study. L.H., Y.D., L.Q., M.D., C.Q., J.L. and L.W. performed the literature review and writing. Y. D. and L.H. wrote the manuscript. All authors critically revised, and provided the final approval for this manuscript.

Conflict of interests

The authors declare no competing financial interests related to this paper.

Acknowledgements

This research was supported by the National Natural Science Foundation of China (No. 81670895 and 81970839 to L.H., 81700841 to J.L.) and the Department of Science and Technology of Sichuan Province, China (No. 21ZDYF0551 to L.H; 2016FZ0091 to Ling Wan).

Appendix A. Supplementary data

Supplementary data to this article can be found online at <https://doi.org/10.1016/j.gendis.2021.02.009>.

References

1. Davis MD, Gangnon RE, Lee LY, et al. The Age-Related Eye Disease Study severity scale for age-related macular degeneration: AREDS Report No. 17. *Arch Ophthalmol*. 2005; 123(11):1484–1498.
2. Ferris FL, Davis MD, Clemons TE, et al. A simplified severity scale for age-related macular degeneration: AREDS Report No. 18. *Arch Ophthalmol*. 2005;123(11):1570–1574.
3. Lim LS, Mitchell P, Seddon JM, Holz FG, Wong TY. Age-related macular degeneration. *Lancet*. 2012;379(9827):1728–1738.
4. Liew G, Joachim N, Mitchell P, Burlutsky G, Wang JJ. Validating the AREDS simplified severity scale of age-related macular degeneration with 5- and 10-year incident data in a population-based sample. *Ophthalmology*. 2016;123(9): 1874–1878.
5. Fine SL, Berger JW, Maguire MG, Ho AC. Age-related macular degeneration. *N Engl J Med*. 2000;342(7):483–492.
6. Laude A, Cackett PD, Vithana EN, et al. Polypoidal choroidal vasculopathy and neovascular age-related macular degeneration: same or different disease? *Prog Retin Eye Res*. 2010; 29(1):19–29.
7. Varma R, Choudhury F, Chen S, et al. Prevalence of age-related macular degeneration in Chinese American adults: the Chinese American eye study. *JAMA Ophthalmol*. 2016; 134(5):571–577.
8. Yeung L, Kuo CN, Chao AN, et al. Angiographic subtypes of polypoidal choroidal vasculopathy in taiwan: a prospective multicenter study. *Retina*. 2018;38(2):263–271.
9. Jonas JB. Global prevalence of age-related macular degeneration. *Lancet Glob Health*. 2014;2(2):65–66.
10. Wong WL, Su X, Li X, et al. Global prevalence of age-related macular degeneration and disease burden projection for 2020 and 2040: a systematic review and meta-analysis. *Lancet Glob Health*. 2014;2(2):106–116.
11. Kawasaki R, Yasuda M, Song SJ, et al. The prevalence of age-related macular degeneration in Asians: a systematic review and meta-analysis. *Ophthalmology*. 2010;117(5):921–927.
12. Friedman DS, O'Colmain BJ, Muñoz B, et al. Prevalence of age-related macular degeneration in the United States. *Arch Ophthalmol*. 2004;122(4):564–572.
13. Klein R, Klein BE, Knudtson MD, et al. Prevalence of age-related macular degeneration in 4 racial/ethnic groups in the multi ethnic study of atherosclerosis. *Ophthalmology*. 2006; 113(3):373–380.
14. Klein R, Chou CF, Klein BE, Zhang X, Meuer SM, Saaddine JB. Prevalence of age-related macular degeneration in the US population. *Arch Ophthalmol*. 2011;129(1):75–80.
15. Reibaldi M, Longo A, Pulvirenti A, et al. Geo-Epidemiology of age-related macular degeneration: new clues into the pathogenesis. *Am J Ophthalmol*. 2016;161:78–93.

16. Song P, Du Y, Chan KY, Theodoratou E, Rudan I. The national and subnational prevalence and burden of age-related macular degeneration in China. *J Glob Health*. 2017;7(2):020703.
17. Chakravarthy U, Elisabeth P, Astrid F, et al. Clinical risk factors for age-related macular degeneration: a systematic review and meta-analysis. *BMC Ophthalmol*. 2010;10(1):31.
18. Rastogi N, Smith RT. Association of age-related macular degeneration and reticular macular disease with cardiovascular disease. *Surv Ophthalmol*. 2016;61(4):422–433.
19. Choudhury F, Varma R, McKean-Cowdin R, Klein R, Azen SP. Risk factors for four-year incidence and progression of age-related macular degeneration: the los angeles latino eye study. *Am J Ophthalmol*. 2011;152(3):385–395.
20. Fischer T. The age-related macular degeneration as a vascular disease/part of systemic vasculopathy: contributions to its pathogenesis. *Orv Hetil*. 2015;156(9):358–365.
21. Srinivasan S, Swaminathan G, Kulothungan V, Ganesan S, Sharma T, Raman R. Age-related macular degeneration in a South Indian population, with and without diabetes. *Eye (Lond)*. 2017;31(8):1176–1183.
22. Choi JK, Lym YL, Moon JW, Shin HJ, Cho B. Diabetes mellitus and early age-related macular degeneration. *Arch Ophthalmol*. 2011;129(2):196–199.
23. Klein R, Knudtson MD, Lee KE, Klein BE. Serum cystatin C level, kidney disease markers, and incidence of age-related macular degeneration: the Beaver Dam Eye Study. *Arch Ophthalmol*. 2009;127(2):193–199.
24. Houston T. Smoking and age-related macular degeneration. *Am Fam Phys*. 2001;63(2):826.
25. Bhatiwada N, Bangera Sheshappa M, Prabhu P, Baskaran V. Dietary and lifestyle risk factors associated with age-related macular degeneration: a hospital based study. *Indian J Ophthalmol*. 2013;61(12):722–727.
26. Chong EW, Kreis AJ, Wong TY, Simpson JA, Guymer RH. Alcohol consumption and the risk of age-related macular degeneration: a systematic review and meta-analysis. *Am J Ophthalmol*. 2008;145(4):707–715.
27. Humphries JM, Khachik F. Distribution of lutein, zeaxanthin, and related geometrical isomers in fruit, vegetables, wheat, and pasta products. *J Agric Food Chem*. 2003;51(5):1322–1327.
28. Merle BMJ, Silver RE, Rosner B, Seddon JM. Associations between vitamin D intake and progression to incident advanced age-related macular degeneration. *Invest Ophthalmol Vis Sci*. 2017;58(11):4569–4578.
29. Zhu W, Wu Y, Meng YF, Xing Q, Tao JJ, Lu J. Fish consumption and age-related macular degeneration incidence: a meta-analysis and systematic review of prospective cohort studies. *Nutrients*. 2016;8(11):743–756.
30. Weikel KA, Chiu CJ, Taylor A. Nutritional modulation of age-related macular degeneration. *Mol Aspects Med*. 2012;33(4):318–375.
31. Swenor BK, Bressler S, Caulfield L, West SK. The impact of fish and shellfish consumption on age-related macular degeneration. *Ophthalmology*. 2010;117(12):2395–2401.
32. Chiu CJ, Klein R, Milton RC, Gensler G, Taylor A. Does eating particular diets alter the risk of age-related macular degeneration in users of the Age-Related Eye Disease Study supplements? *Br J Ophthalmol*. 2009;93(9):1241–1246.
33. Merle BM, Benlian P, Puche N, et al. Circulating omega-3 Fatty acids and neovascular age-related macular degeneration. *Invest Ophthalmol*. 2014;55(3):2010–2019.
34. Anastasopoulos E, Haidich AB, Coleman AL, et al. Risk factors for age-related macular degeneration in a Greek population: the thessaloniki eye study. *Ophthalmic Epidemiol*. 2018;25(5–6):457–469.
35. Fritsche LG, Fariss RN, Stambolian D, Abecasis GR, Curcio CA, Swaroop A. Age-related macular degeneration: genetics and biology coming together. *Annu Rev Genom Hum Genet*. 2014;15:151–171.
36. Klein RJ, Zeiss C, Chew EY, et al. Complement factor H polymorphism in age-related macular degeneration. *Science*. 2005;308(5720):385–389.
37. Haines JL, MHAuser MA, Schmidt S, et al. Complement factor H variant increases the risk of age-related macular degeneration. *Science*. 2005;308(5720):419–421.
38. Edwards AO, Ritter R, Abel KJ, Manning A, Panhuysen C, Farrer LA. Complement factor H polymorphism and age-related macular degeneration. *Science*. 2005;308(5720):421–424.
39. Sepp T, Khan JC, Thurlby DA, et al. Complement factor H variant Y402H is a major risk determinant for geographic atrophy and choroidal neovascularization in smokers and nonsmokers. *Invest Ophthalmol Vis Sci*. 2006;47(2):536–540.
40. Despret DD, Klaver CCW, Wittteman JCM, et al. Complement factor H polymorphism, complement activators, and risk of age-related macular degeneration. *JAMA*. 2006;296(3):301–309.
41. Kaur L, Katta S, Reddy RK, et al. The involvement of complement factor B and complement component C2 in an Indian cohort with age-related macular degeneration. *Invest Ophthalmol Vis Sci*. 2010;51(1):59–63.
42. Johnson LV, Leitner WP, Staples MK, Anderson DH. Complement activation and inflammatory processes in Drusen formation and age-related macular degeneration. *Exp Eye Res*. 2001;73(6):887–896.
43. Nozaki M, Raisler BJ, Sakurai E, et al. Drusen complement components C3a and C5a promote choroidal neovascularization. *Proc Natl Acad Sci USA*. 2006;103(7):2328–2333.
44. Ennis S, Gibson J, Cree AJ, Collins A, Lotery AJ. Support for the involvement of complement factor I in age-related macular degeneration. *Eur J Hum Genet*. 2010;18(1):15–16.
45. Deangelis MM, Ji F, Adams S, et al. Alleles in the Htra serine peptidase 1 gene alter the risk of neovascular age-related macular degeneration. *Ophthalmology*. 2008;115(7):1209–1215.
46. Dewan A, Liu M, Hartman S, et al. HTRA1 promoter polymorphism in wet age-related macular degeneration. *Science*. 2006;314(5801):989–992.
47. Fritsche LG, Loenhardt T, Janssen A, et al. Age-related macular degeneration is associated with an unstable ARMS2 (LOC387715) mRNA. *Nat Genet*. 2008;40(7):892–896.
48. Hughes AE, Nick O, Chris P, et al. Neovascular age-related macular degeneration risk based on CFH, LOC387715/HTRA1, and smoking. *PLoS Med*. 2007;4(12):e355.
49. Rivera A, Fisher SA, Fritsche LG, et al. Hypothetical LOC387715 is a second major susceptibility gene for age-related macular degeneration, contributing independently of complement factor H to disease risk. *Hum Mol Genet*. 2005;14(21):3227–3236.
50. Schmidt S, Hauser MA, Scott WK, et al. Cigarette smoking strongly modifies the association of LOC387715 and age-related macular degeneration. *Am J Hum Genet*. 2006;78(5):852–864.
51. Seddon JM, Francis PJ, George S, Schultz DW, Rosner B, Klein ML. Association of CFH Y402H and LOC387715 A69S with progression of age-related macular degeneration. *JAMA*. 2007;297(16):1793–1800.
52. Wang G, Spencer KL, Scott WK, et al. Analysis of the indel at the ARMS2 3'UTR in age-related macular degeneration. *Hum Genet*. 2010;127(5):595–602.

53. Yang Z, Camp NJ, Sun H, et al. A variant of the HTRA1 gene increases susceptibility to age-related macular degeneration. *Science*. 2006;314(5801):992–993.
54. Yang Z, Tong Z, Chen Y, et al. Genetic and functional dissection of HTRA1 and LOC387715 in age-related macular degeneration. *PLoS Genet*. 2010;6(2):e1000836.
55. Ishida BY, Bailey KR, Duncan KG, et al. Regulated expression of apolipoprotein E by human retinal pigment epithelial cells. *J Lipid Res*. 2004;45(2):263–271.
56. Anderson DH, Ozaki S, Nealon M, et al. Local cellular sources of apolipoprotein E in the human retina and retinal pigmented epithelium: implications for the process of drusen formation. *Am J Ophthalmol*. 2001;131(6):767–781.
57. Li CM, Clark ME, Chimento MF, Curcio CA. Apolipoprotein localization in isolated drusen and retinal apolipoprotein gene expression. *Invest Ophthalmol Vis Sci*. 2006;47(7):3119–3128.
58. Eiriksdottir G, Aspelund T, Bjarnadottir K, et al. Apolipoprotein E genotype and statins affect CRP levels through independent and different mechanisms: AGES-Reykjavik Study. *Atherosclerosis*. 2006;186(1):222–224.
59. Strunnikova NV, Maminishkis A, Barb JJ, et al. Transcriptome analysis and molecular signature of human retinal pigment epithelium. *Hum Mol Genet*. 2010;19(12):2468–2486.
60. Gliem M, Müller PL, Mangolde E, et al. Sorsby fundus dystrophy: novel mutations, novel phenotypic characteristics, and treatment outcomes. *Invest Ophthalmol Vis Sci*. 2015;56(4):2664–2676.
61. Neale BM, Fagerness J, Reynoldset R, et al. Genome-wide association study of advanced age-related macular degeneration identifies a role of the hepatic lipase gene (LIPC). *Proc Natl Acad Sci USA*. 2010;107(16):7395–7400.
62. Tserentsoodol N, Gordiyenko NV, Pascual I, Lee JW, Fliesler SJ, Rodriguez IR. Intraretinal lipid transport is dependent on high density lipoprotein-like particles and class B scavenger receptors. *Mol Vis*. 2006;12:1319–1333.
63. Ennis S, Jomary C, Mullins R, et al. Association between the SERPING1 gene and age-related macular degeneration: a two-stage case-control study. *Lancet*. 2008;372(9652):1828–1834.
64. Huang L, Zhang H, Chen CY, et al. A missense variant in FGD6 confers increased risk of polypoidal choroidal vasculopathy. *Nat Genet*. 2016;48(6):640–647.
65. Kew RR, Ghebrehiwet B, Janoff A. Cigarette smoke can activate the alternative pathway of complement in vitro by modifying the third component of complement. *J Clin Invest*. 1985;75(3):1000–1007.
66. Esparza-Gordillo J, Soria JM, Buil A, et al. Genetic and environmental factors influencing the human factor H plasma levels. *Immunogenetics*. 2004;56(2):77–82.
67. DeAngelis MM, Ji F, Kim IK, et al. Cigarette smoking, CFH, APOE, ELOVL4, and risk of neovascular age-related macular degeneration. *Arch Ophthalmol*. 2007;125(1):49–54.
68. Schaumberg DA, Hankinson SE, Guo Q, Rimm E, Hunter DJ. A prospective study of 2 major age-related macular degeneration susceptibility alleles and interactions with modifiable risk factors. *Arch Ophthalmol*. 2007;125(1):55–62.
69. Scott WK, Schmidt S, Hauser MA, et al. Independent effects of complement factor H Y402H polymorphism and cigarette smoking on risk of age-related macular degeneration. *Ophthalmology*. 2007;114(6):1151–1156.
70. Seddon JM, George S, Rosner B, Klein ML. CFH gene variant, Y402H, and smoking, body mass index, environmental associations with advanced age-related macular degeneration. *Hum Hered*. 2006;61(3):157–165.
71. Sobrin L, Seddon JM. Nature and nurture- genes and environment- predict onset and progression of macular degeneration. *Prog Retin Eye Res*. 2014;40:1–15.
72. Wang JJ, Rochtchina E, Smith W, et al. Combined effects of complement factor H genotypes, fish consumption, and inflammatory markers on long-term risk for age-related macular degeneration in a cohort. *Am J Epidemiol*. 2009;169(5):633–641.
73. Ho L, van Leeuwen R, Witteman JC, et al. Reducing the genetic risk of age-related macular degeneration with dietary antioxidants, zinc, and omega-3 fatty acids: the Rotterdam study. *Arch Ophthalmol*. 2011;129(6):758–766.
74. Wang JJ, Buitendijk GHS, Rochtchina E, et al. Genetic susceptibility, dietary antioxidants, and long-term incidence of age-related macular degeneration in two populations. *Ophthalmology*. 2014;121(3):667–675.
75. Seddon JM, Gensler G, Rosner B. C-reactive protein and CFH, ARMS2/HTRA1 gene variants are independently associated with risk of macular degeneration. *Ophthalmology*. 2010;117(8):1560–1566.
76. Naj AC, Scott WK, Courtenay MD, et al. Genetic factors in nonsmokers with age-related macular degeneration revealed through genome-wide gene-environment interaction analysis. *Ann Hum Genet*. 2013;77(3):215–231.
77. Schmidt S, Haines JL, Postel EA, et al. Joint effects of smoking history and APOE genotypes in age-related macular degeneration. *Mol Vis*. 2005;11:941–949.
78. Schmidt S, Saunders AM, De La Paz MA, et al. Association of the apolipoprotein E gene with age-related macular degeneration: possible effect modification by family history, age, and gender. *Mol Vis*. 2000;6:287–293.
79. Del Priore LV, Kuo YH, Tezel TH. Age-related changes in human RPE cell density and apoptosis proportion in situ. 2002; 43(10):3312–3318.
80. Ciulla TA. Evolving pathophysiological paradigms for age related macular degeneration. *Br J Ophthalmol*. 2001;85(5):510–512.
81. van Lookeren Campagne M, LeCouter J, Yaspan BL, Ye W. Mechanisms of age-related macular degeneration and therapeutic opportunities. *J Pathol*. 2014;232(2):151–164.
82. Beatty S, Koh H, Phil M, Henson D, Boulton M. The role of oxidative stress in the pathogenesis of age-related macular degeneration. *Surv Ophthalmol*. 2000;45(2):115–134.
83. Khandhadia S, Lotery A. Oxidation and age-related macular degeneration: insights from molecular biology. *Expert Rev Mol Med*. 2010;12:e34.
84. Feeney-Burns L, Hilderbrand ES, Eldridge S. Aging human RPE: morphometric analysis of macular, equatorial, and peripheral cells. *Invest Ophthalmol Vis Sci*. 1984;25(2):195–200.
85. Schmitz-Valckenberg S, Fleckenstein M, Scholl HP, Holz FG. Fundus autofluorescence and progression of age-related macular degeneration. *Surv Ophthalmol*. 2009;54(1):96–117.
86. Sui GY, Liu GC, Liu GY, et al. Is sunlight exposure a risk factor for age-related macular degeneration? A systematic review and meta-analysis. *Br J Ophthalmol*. 2013;97(4):389–394.
87. Clemons TE, Milton RC, Klein R, Seddon JM, Ferris FL. Risk factors for the incidence of advanced age-related macular degeneration in the age-related eye disease study (AREDS) AREDS report no. 19. *Ophthalmology*. 2004;112(4):533–539.
88. Hanus J, Anderson C, Wang S. RPE necroptosis in response to oxidative stress and in AMD. *Ageing Res Rev*. 2015;24(PtB):286–298.
89. Hyttinen JM, Petrovski G, Salminen A, Kaarniranta K. 5'-Adenosine monophosphate-activated protein kinase-mammalian target of rapamycin axis as therapeutic target for age-related macular degeneration. *Rejuvenation Res*. 2011;14(6):651–660.
90. Hyttinen JMT, Blasiak J, Niittykoski M, et al. DNA damage response and autophagy in the degeneration of retinal pigment epithelial cells-implications for age-related macular degeneration (AMD). *Ageing Res Rev*. 2017;36:64–77.

91. Wang Y, Wang M, Zhang X, et al. The association between the lipids levels in blood and risk of age-related macular degeneration. *Nutrients*. 2016;8(10):663–677.
92. Sparrow JR, Fishkin N, Zhou, et al. A2E, a byproduct of the visual cycle. *Vis Res*. 2003;43(28):2983–2990.
93. Zhou J, Jang YP, Kim SR, Sparrow JR. Complement activation by photooxidation products of A2E, a lipofuscin constituent of the retinal pigment epithelium. *Proc Natl Acad Sci USA*. 2006;103(44):16182–16187.
94. Seddon JM, Gensler G, Milton RC, Klein ML, Rifai N. Association between C-reactive protein and age-related macular degeneration. *JAMA*. 2004;291(6):704–710.
95. Lauer N, Mihlan M, Hartmann A, et al. Complement regulation at necrotic cell lesions is impaired by the age-related macular degeneration-associated factor-H His402 risk variant. *J Immunol*. 2011;187(8):4374–4383.
96. Clark SJ, McHarg S, Tilakaratna V, Brace N, Bishop PN. Bruch's membrane compartmentalizes complement regulation in the eye with implications for therapeutic design in age-related macular degeneration. *Front Immunol*. 2017;8:1778.
97. Park DH, Connor KM, Lambris JD. The challenges and promise of complement therapeutics for ocular diseases. *Front Immunol*. 2019;10:1007.
98. Calippe B, Augustin S, Beguier F, et al. Complement factor H inhibits CD47-mediated resolution of inflammation. *Immunity*. 2017;46(2):261–272.
99. Campochiaro PA, Soloway P, Ryan SJ, Miller JW. The pathogenesis of choroidal neovascularization in patients with age-related macular degeneration. *Mol Vis*. 1999;5:34.
100. Mori F, Konno S, Hikichi T, Yamaguchi Y, Ishiko S, Yoshida A. Pulsatile ocular blood flow study: decreases in exudative age-related macular degeneration. *Br J Ophthalmol*. 2001;85(5):531–533.
101. Friedman E, Krupsky S, Lane AM, et al. Ocular blood flow velocity in age-related macular degeneration. *Ophthalmology*. 1995;102(4):640–646.
102. Friedman E, Ivry M, Ebert E, Glynn R, Gragoudas E, Seddon J. Increased scleral rigidity and age-related macular degeneration. *Ophthalmology*. 1989;96(1):104–108.
103. Tufail AF, Holz D, Pauleikhoff RF, Spaide AC, Bird. Age-related macular degeneration. *Graefes Arch Clin Exp Ophthalmol*. 2007;245(9):1409–1410.
104. Bowes Rickman C, Farsiu S, Toth CA, Klingeborn M. Dry age-related macular degeneration: mechanisms, therapeutic targets, and imaging. *Invest Ophthalmol Vis Sci*. 2013;54(14):68–80.
105. Ferrington DA, Sinha D, Kaarniranta K. Defects in retinal pigment epithelial cell proteolysis and the pathology associated with age-related macular degeneration. *Prog Retin Eye Res*. 2016;51:69–89.
106. Golestaneh N, Chu Y, Xiao YY, Stoleru GL, Theos AC. Dysfunctional autophagy in RPE, a contributing factor in age-related macular degeneration. *Cell Death Dis*. 2017;8(1):e2537.
107. Friedman E. A hemodynamic model of the pathogenesis of age-related macular degeneration. *Am J Ophthalmol*. 1997;124(5):677–682.
108. Gelfand BD, Ambati JA. Revised hemodynamic theory of age-related macular degeneration. *Trends Mol Med*. 2016;22(8):656–670.
109. Bhatwadekar AD, Yan Y, Qi X, et al. Per2 mutation recapitulates the vascular phenotype of diabetes in the retina and bone marrow. *Diabetes*. 2013;62(1):273–282.
110. Busik JV, Tikhonenko M, Bhatwadekar A, et al. Diabetic retinopathy is associated with bone marrow neuropathy and a depressed peripheral clock. *J Exp Med*. 2009;206(13):2897–2906.
111. Cassels NK, Wild JM, Margrain TH, Chong V, Acton JH. The use of microperimetry in assessing visual function in age-related macular degeneration. *Surv Ophthalmol*. 2018;63(1):40–55.
112. Schmidt-Erfurth U, Klmscha S, Waldstein SM, Bogunovic H. A view of the current and future role of optical coherence tomography in the management of age-related macular degeneration. *Eye*. 2017;31(1):26–44.
113. Schuman SG, Koreishi AF, Farsiu S, Jung SH, Izatt JA, Toth CA. Photoreceptor layer thinning over drusen in eyes with age-related macular degeneration imaged in vivo with spectral-domain optical coherence tomography. *Ophthalmology*. 2009;116(3):488–496.
114. Manjunath V, Goren J, Fujimoto JG, Duker JS. Analysis of choroidal thickness in age-related macular degeneration using spectral-domain optical coherence tomography. *Am J Ophthalmol*. 2011;152(4):663–668.
115. Cicinelli MV, Rabiolo A, Sacconi R, et al. Optical coherence tomography angiography in dry age-related macular degeneration. *Surv Ophthalmol*. 2018;63(2):236–244.
116. Boltz A, Luksch A, Wimpissingeret B, et al. Choroidal blood flow and progression of age-related macular degeneration in the fellow eye in patients with unilateral choroidal neovascularization. *Invest Ophthalmol Vis Sci*. 2010;51(8):4220–4225.
117. Bhutto IA, Uno K, Merges C, Zhang L, McLeod DS, Luty GA. Reduction of endogenous angiogenesis inhibitors in Bruch's membrane of the submacular region in eyes with age-related macular degeneration. *Arch Ophthalmol*. 2008;126(5):670–678.
118. Cicinelli MV, Cavalleri M, Consorte AC, et al. Swept-source and spectral domain optical coherence tomography angiography versus dye angiography in the measurement of type 1 neovascularization. *Retina*. 2019;40(3):499–506.
119. Moulton E, Choi WJ, Waheed NK, et al. Ultrahigh-speed swept-source OCT angiography in exudative AMD. *Ophthalmic Surg Lasers Imag Ret*. 2014;45(6):496–505.
120. Jia Y, Bailey ST, Wilson DJ, et al. Quantitative optical coherence tomography angiography of choroidal neovascularization in age-related macular degeneration. *Ophthalmology*. 2014;121(7):1435–1444.
121. Cheung CMG, Yanagi Y, Akiba M, et al. Improved detection and diagnosis of polypoidal choroidal vasculopathy using a combination of optical coherence tomography and optical coherence tomography angiography. *Retina*. 2019;39(9):1655–1663.
122. Ma J, Desai R, Nesper P, Gill M, Fawzi A, Skondra D. Optical coherence tomographic angiography imaging in age-related macular degeneration. *Ophthalmol Eye Dis*. 2017;9:1–7.
123. Kermany DS, Goldbaum M, Cai W, et al. Identifying medical diagnoses and treatable diseases by image-based deep learning. *Cell*. 2018;172(5):1122–1131.
124. Treder M, Lauermann JL, Eter N. Automated detection of exudative age-related macular degeneration in spectral domain optical coherence tomography using deep learning. *Graefes Arch Clin Exp*. 2018;256(2):259–265.
125. Reichel E, Berroca A, Michael I, et al. Transpupillary thermotherapy of occult subfoveal choroidal neovascularization in patients with age-related macular degeneration. *Ophthalmology*. 1999;106(10):1908–1914.
126. Agnieszka KT. Transpupillary thermotherapy (TTT) with injections of triamcinolone acetonide under posterior Tenon's capsule in the treatment of exudative age-related macular degeneration (AMD). *Klin Oczna*. 2010;112(10–12):289–292.
127. Söderberg AC, Algvere PV, Hengstler JC, Söderberg P, Seregard S, Kvanta A. Combination therapy with low-dose transpupillary thermotherapy and intravitreal ranibizumab for neovascular age-related macular degeneration: a 24-

- month prospective randomised clinical study. *Br J Ophthalmol*. 2012;96(5):714–718.
128. Kumar Chhablani J. Photodynamic therapy for polypoidal choroidal vasculopathy. *Am J Ophthalmol*. 2010;150(5):754–755.
 129. Chappelov AV, Kaiser PK. Neovascular age-related macular degeneration: potential therapies. *Drugs*. 2008;68(8):1029–1036.
 130. Hamilton WS. New treatments for age-related macular degeneration. *Lancet*. 2007;370(9597):1480–1481.
 131. Rosenfeld PJ, Brown DM, Heier JS, et al. Ranibizumab for neovascular age-related macular degeneration. *N Engl J Med*. 2006;355(14):1419–1431.
 132. Brown DM, Kaiser PK, Michels M, et al. Ranibizumab versus verteporfin for neovascular age-related macular degeneration. *N Engl J Med*. 2006;355(14):1432–1444.
 133. Cheung N, Wong TY. Changing trends of blindness: the initial harvest from translational public health and clinical research in ophthalmology. *Am J Ophthalmol*. 2012;153(2):193–195.
 134. Hikichi T, Agarie M. Reduced vessel density of the choriocapillaris during anti-vascular endothelial growth factor therapy for neovascular age-related macular degeneration. *Invest Ophthalmol Vis Sci*. 2019;60(4):1088–1095.
 135. Ng EW, Shima DT, Calias P, Cunningham Jr ET, Guyer DR, Adamis AP. Pegaptanib, a targeted anti-VEGF aptamer for ocular vascular disease. *Nat Rev Drug Discov*. 2006;5(2):123–132.
 136. Gragoudas ES, Adamis AP, Cunningham Jr ET, Feinsod M, Guyer DR. VEGF inhibition study in ocular neovascularization clinical trial group. Pegaptanib for neovascular age-related macular degeneration. *N Engl J Med*. 2004;351(27):2805–2816.
 137. Holash J, Davis S, Papadopoulos N, et al. VEGF-Trap: a VEGF blocker with potent antitumor effects. *Proc Natl Acad Sci USA*. 2002;99(17):11393–11398.
 138. Heier JS, Brown DM, Chonget V, et al. Intravitreal aflibercept (VEGF trap-eye) in wet age-related macular degeneration. *Ophthalmology*. 2012;119(12):2537–2548.
 139. Zhang M, Zhang J, Yan M, Li H, Yang C, Yu D. Recombinant anti-vascular endothelial growth factor fusion protein efficiently suppresses choroidal neovascularization in monkeys. *Mol Vis*. 2008;14:37–49.
 140. Zhang M, Yu D, Yang C, et al. The pharmacology study of a new recombinant human VEGF receptor-fc fusion protein on experimental choroidal neovascularization. *Pharmaceut Res*. 2009;26(1):204–210.
 141. Li X, Xu G, Wang Y, et al. Safety and efficacy of conbercept in neovascular age-related macular degeneration: results from a 12-month randomized phase 2 study: AURORA study. *Ophthalmology*. 2014;121(9):1740–1747.
 142. Dugel PU, Adrian Koh F, Ogura Y, et al. HAWK and HARRIER: phase 3, multicenter, randomized, double-masked trials of brolucizumab for neovascular age-related macular degeneration. *Ophthalmology*. 2020;127(1):72–84.
 143. Khanani AM, Patel SS, Ferrone PJ, et al. Efficacy of every four monthly and quarterly dosing of faricimab vs ranibizumab in neovascular age-related macular degeneration the STAIRWAY phase 2 randomized clinical trial. *JAMA Ophthalmol*. 2020;138(9):964–972.
 144. Kunitomo D, Ohji M, Maturi RK, et al. Evaluation of abicipar pegol (an anti-VEGF DARPIN therapeutic) in patients with neovascular age-related macular degeneration: studies in Japan and the United States. *Ophthalm Surg Lasers Imag Ret*. 2019;50:e10–e12.
 145. Age-Related Eye Disease Study Research Group. A randomized, placebo-controlled, clinical trial of high-dose supplementation with vitamins C and E and beta carotene for age-related cataract and vision loss: AREDS report no. 9. *Arch Ophthalmol*. 2001;119(10):1439–1452.
 146. Flood MT, Gouras P, Kjeldbye H. Growth characteristics and ultrastructure of human retinal pigment epithelium in vitro. *Investig Ophthalmol Vis Sci*. 1980;19(11):1309–1320.
 147. Boulton ME, Marshall J, Mellerio J. Human retinal pigment epithelial cells in tissue culture: a means of studying inherited retinal diseases. *Birth Defects Orig Artic Ser*. 1982;18(6):101–118.
 148. Hu DN, Del Monte MA, Liu S, Maumenee IH. Morphology, phagocytosis, and vitamin A metabolism of cultured human retinal pigment epithelium. *Birth Defects Orig Artic Ser*. 1982;18(6):67–79.
 149. Chen FK, Patel PJ, Uppal GS, Tufail A, Coffey PJ, Da Cruz L. Long-term outcomes following full macular translocation surgery in neovascular age-related macular degeneration. *Br J Ophthalmol*. 2010;94(10):1337–1343.
 150. Cahill MT, Freedman SF, Toth CA. Macular translocation with 360 degrees peripheral retinectomy for geographic atrophy. *Arch Ophthalmol*. 2003;121(1):132–133.
 151. Thumann G, Viethen A, Gaebler A, et al. The in vitro and in vivo behaviour of retinal pigment epithelial cells cultured on ultrathin collagen membranes. *Biomaterials*. 2009;30(3):287–294.
 152. Stanzel BV, Liu Z, Brinken R, Braun N, Holz FG, Eter N. Subretinal delivery of ultrathin rigid-elastic cell carriers using a metallic shooter instrument and biodegradable hydrogel encapsulation. *Invest Ophthalmol Vis Sci*. 2012;53(1):490–500.
 153. Lappas A, Foerster AM, Weinberger AW, Coburger S, Schrage NF, Kirchhof B. Translocation of iris pigment epithelium in patients with exudative age-related macular degeneration: long-term results. *Graefes Arch Clin Exp Ophthalmol*. 2004;42(8):638–647.
 154. Li LX, Turner JE. Inherited retinal dystrophy in the RCS rat: prevention of photoreceptor degeneration by pigment epithelial cell transplantation. *Exp Eye Res*. 1988;47(6):911–917.
 155. Lopez R, Gouras P, Brittis M, Kjeldbye H. Transplantation of cultured rabbit retinal epithelium to rabbit retina using a closed-eye method. *Invest Ophthalmol Vis Sci*. 1987;28(7):1131–1137.
 156. Gouras P, Alverre P. Retinal cell transplantation in the macula: new techniques. *Vis Res*. 1996;36(24):4121–4125.
 157. Alexander P, Thomson HA, Luff AJ, Lotery AJ. Retinal pigment epithelium transplantation: concepts, challenges, and future prospects. *Eye*. 2015;29(8):992–1002.
 158. Akyurt A. Cycloptopia and surgical treatment after macular translocation. *Klin Monbl Augenheilkd*. 2002;219(1–2):50–54.
 159. Machemer R. Macular translocation. *Am J Ophthalmol*. 1998;125(5):698–700.
 160. Polito A, Cereda M, Romanelli F, Pertile G. Macular translocation with 360-degree retinotomy for management of retinal pigment epithelial tear: long-term results. *Br J Ophthalmol*. 2011;95(1):74–78.
 161. Schwartz SD, Hubschman JP, Heilwell G, et al. Embryonic stem cell trials for macular degeneration: a preliminary report. *Lancet*. 2012;379(9817):713–720.
 162. Da Cruz L, Fynes K, Georgiadis O, et al. Phase 1 clinical study of an embryonic stem cell-derived retinal pigment epithelium patch in age-related macular degeneration. *Nat Biotechnol*. 2018;36(4):328–337.
 163. Mandai M, Watanabe A, Kurimoto Y, et al. Autologous induced stem-cell-derived retinal cells for macular degeneration. *N Engl J Med*. 2017;376(11):1038–1046.

164. Ludwig PE, Freeman SC, Janot AC. Novel stem cell and gene therapy in diabetic retinopathy, age related macular degeneration, and retinitis pigmentosa. *Int J Ret Vitro*. 2019;5(1):1–7.
165. Pechan P, Rubin H, Lukason M, et al. Novel anti-VEGF chimeric molecules delivered by AAV vectors for inhibition of retinal neovascularization. *Gene Ther*. 2009;16(1):10–16.
166. Constable IJ, Pierce CM, Lai CM, et al. Phase 2a randomized clinical trial: safety and post hoc analysis of subretinal rAAV.sFLT-1 for wet age-related macular degeneration. *EBioMedicine*. 2016;14:168–175.
167. Heier JS, Kherani S, Desai S, et al. Intravitreal injection of AAV2-sFLT01 in patients with advanced neovascular age-related macular degeneration: a phase 1, open-label trial. *Lancet*. 2017;390(10089):50–61.
168. Igarashi T, Miyake K, Masuda I, Takahashi H, Shimada T. Adeno-associated vector (type 8)-mediated expression of soluble Flt-1 efficiently inhibits neovascularization in a murine choroidal neovascularization model. *Hum Gene Ther*. 2010;21(5):631–637.
169. MacLachlan TK, Lukason M, Collins M, et al. Preclinical safety evaluation of AAV2-sFLT01- a gene therapy for age-related macular degeneration. *Mol Ther*. 2011;19(2):326–334.
170. Rakoczy EP, Lai CM, Magno AL, et al. Gene therapy with recombinant adeno-associated vectors for neovascular age-related macular degeneration: one year follow-up of a phase 1 randomised clinical trial. *Lancet*. 2015;386(10011):2395–2403.
171. Mori Keisuke, Ando Akira, Gehlbach Peter, et al. Inhibition of choroidal neovascularization by intravenous injection of adenoviral vectors expressing secretable endostatin. *Am J Pathol*. 2001;159(1):313–320.
172. Raisler BJ, Berns KI, Grant MB, Beliaev D, Hauswirth WW. Adeno-associated virus type-2 expression of pigmented epithelium-derived factor or Kringle 1-3 of angiostatin reduce retinal neovascularization. *Proc Natl Acad Sci USA*. 2002;99(13):8909–8914.
173. Lai LJ, Xiao X, Wu JH. Inhibition of corneal neovascularization with endostatin delivered by adeno-associated viral (AAV) vector in a mouse corneal injury model. *J Biomed Sci*. 2007;14(3):313–322.
174. Thumann GP-DM, Izsvak Z. Transposon-based, targeted ex vivo gene therapy to treat age-related macular degeneration (target AMD). Human gene therapy. *Clin Develop*. 2015;26(2):97–100.
175. Li W, Dong L, Ma M, et al. Preliminary in vitro and in vivo assessment of a new targeted inhibitor for choroidal neovascularization in age-related macular degeneration. *Drug Des Dev Ther*. 2016;10:3415–3423.
176. De Oliveira Dias JR, Rodrigues EB, Maia M, Magalhães Jr O, Penha FM, Farah ME. Cytokines in neovascular age-related macular degeneration: fundamentals of targeted combination therapy. *Br J Ophthalmol*. 2011;95(12):1631–1637.
177. Goodman DM, Parmet S, Lynn C, Livingston EH. Age-related macular degeneration. *JAMA*. 2012;308(16):1702.
178. Kaiser PK. Emerging therapies for neovascular age-related macular degeneration: drugs in the pipeline. *Ophthalmology*. 2013;120(5S):S11–S15.